

Case Report

# Hypercalcemia due to Elevated 1,25 dihydroxyvitamin D in Tophaceous Gout - Case Report and Literature Review

Madhia Ahmad<sup>1,3\*</sup>, Sunnie Lee<sup>2</sup>, Htay Htay Kyi<sup>2</sup>, Shuwei Wang<sup>2</sup>, Smitha Mahendrakar<sup>3</sup> and Michael Yudd<sup>4</sup>

<sup>1</sup>Department of Nephrology, Rutgers New Jersey Medical School, Newark, NJ, USA

<sup>2</sup>Department of Rheumatology, Rutgers New Jersey Medical School, Newark, NJ, USA

<sup>3</sup>East Orange VA, Department of Rheumatology, East Orange, NJ, USA

<sup>4</sup>East Orange VA, Department of Nephrology, East Orange, NJ, USA

## Abstract

Granulomatous diseases can cause hypercalcemia due to elevated 1,25-dihydroxyvitamin D through the production of 1- $\alpha$  hydroxylase by macrophages in the granulomas. Tophaceous gout is not considered to cause this picture. However, there are a few case reports of this occurrence in tophaceous gout, as well as the description of intense 1- $\alpha$  hydroxylase activity in granulomas of tophi in gout patients. We review this literature, and we report a well-documented case of hypercalcemia with elevated serum 1,25 dihydroxyvitamin D in a patient with extensive tophaceous gout and tophi loaded with granulomas. An extensive work-up ruled out other causes of hypercalcemia and granulomatous diseases. Prednisone corrected the chemical abnormalities. Diffuse tophaceous gout should be considered a rare cause of hypercalcemia due to excessive 1,25 dihydroxy vitamin D.

## Introduction

Hypercalcemia is commonly encountered in clinical practice. Primary hyperparathyroidism and malignancy encompass nearly 90% of cases of hypercalcemia [1]. Less common etiologies of hypercalcemia include granulomatous diseases, endocrinopathies, familial disorders, medications, vitamins, and immobilization [1,2]. Many rare causes of hypercalcemia have been reported and recently reviewed [3].

We present a rare case of moderate hypercalcemia in the setting of chronic tophaceous gout due to excessive activation of 1,25 dihydroxy vitamin D and we review the literature.

## Case presentation

The patient is a 68-year-old man who was referred to the renal clinic for hypercalcemia of 13.1 mg/dL and worsening renal function. On review, hypercalcemia was present for at least 10 months. He complained of decreased energy, but in general, felt well. He denied confusion, nausea and vomiting, weight change, fever, or cough.

The patient had a longstanding history of gout diagnosed 15 years earlier that started as podagra. He had intermittent

flares of gout for 5 years, but for the last 10 years, these were limited with occasional treatments with allopurinol and prednisone. He noticed painless tophi on his hands 10 years ago that gradually enlarged and spread to his forearms, elbows, and calves. Both left and right elbow tophi were debulked. Negative birefringent monosodium urate crystals were found in the tophi. His medical problems included hypertension, Chronic Kidney Disease (CKD), atrial fibrillation, and gastroesophageal reflux disease. His medications were allopurinol 300 mg daily, apixaban, diltiazem, and pantoprazole.

On the physical exam, the patient was alert and in no distress. He was afebrile with a blood pressure of 130/80 mm Hg, a heart rate of 70 beats /min; BMI was 28. His skin was moist. Lungs were clear, the heart showed a regular rhythm without murmurs, and the abdomen was soft without organomegaly. There was no lymphadenopathy or edema. There were severe, diffuse tophi and deformities in both hands, elbows, forearms, calves, toes, and ears (Image 1). There was no appreciable synovitis or tender joints.

Serum calcium was 13.1 mg/dl/dl (normal 8.2–10.7 mg/dl) and ionized calcium was 6.2 mg/dl (normal 4.5–5.3 mg/dl). On review, serum calcium was elevated from 11.0 - 13.1 mg/dl

### More Information

#### \*Address for correspondence:

Madhia Ahmad, MD, Department of Nephrology, Rutgers New Jersey Medical School, Newark, NJ, USA, Email: mba110@njms.rutgers.edu

Submitted: October 22, 2024

Approved: November 21, 2024

Published: November 22, 2024

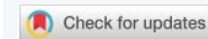#### How to cite this article:

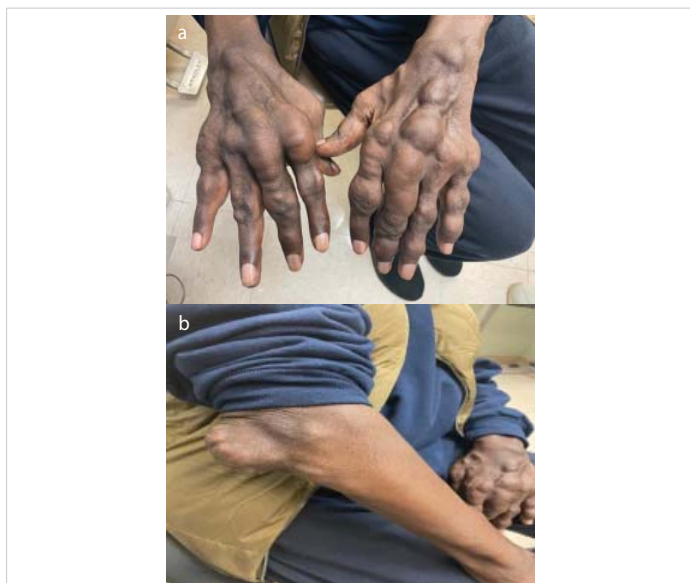
Ahmad M, Lee S, Kyi HH, Wang S, Mahendrakar S, Yudd M. Hypercalcemia due to Elevated 1,25 dihydroxyvitamin D in Tophaceous Gout - Case Report and Literature Review. J Clin Nephrol. 2024; 8(3): 142-145. Available from:

<https://dx.doi.org/10.29328/journal.jcn.1001143>

#### Copyright license:

© 2024 Ahmad M, et al. This is an open access article distributed under the Creative Commons Attribution License, which permits unrestricted use, distribution, and reproduction in any medium, provided the original work is properly cited.





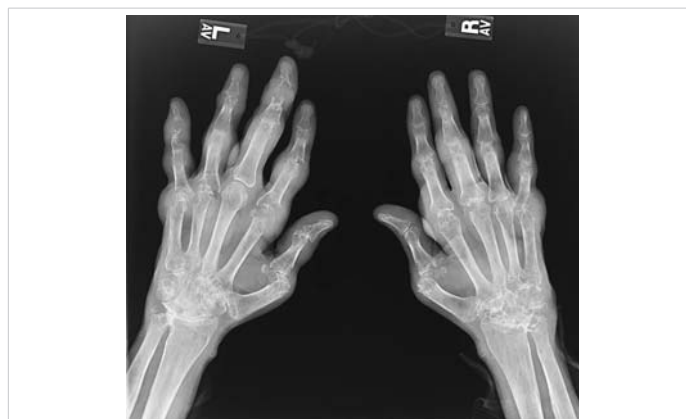**Image 1:** a,b: Large tophus over bilateral hands and right elbow.

for at least 10 months. Uric acid was 9.8 mg/dl and serum albumin was 4.0 g/dl. Serum creatinine was 2.6 mg/dl, above his baseline of 2.0 mg/dl. Serum-intact PTH was appropriately suppressed at 2.3 pg/ml (normal 12-88 pg/ml). Both serum 1,25-dihydroxyvitamin D and Angiotensin-Converting Enzyme (ACE) levels were markedly elevated at 87.5 pg/ml (normal 22-67 pg/ml) and 142 units/l (normal 7-46 units/l) respectively. 24-hour urine calcium was also increased at 398 mg/day (normal < 250 mg/day). Serum 25-hydroxyvitamin D was 18 ng/ml (normal 30-100 ng/ml). The following were negative or normal: PTH-related protein, serum and protein immunoelectrophoresis, prostate-specific antigen, thyroid stimulating hormone, cortisol, urine culture, and tuberculin skin test. The following rheumatology studies were negative: rheumatoid factor, anti-CCP, ANA, and HLA B27.

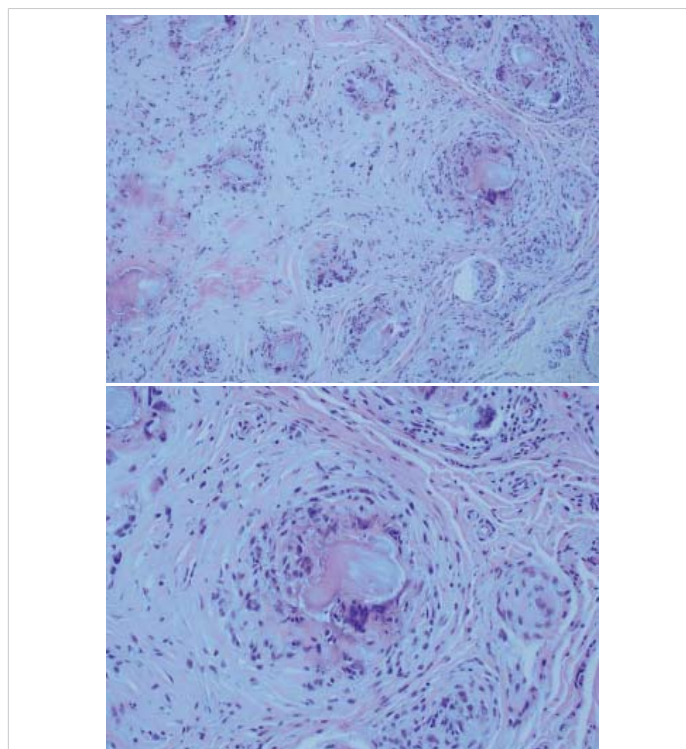
Imaging studies including CT of the chest, abdomen, and pelvis were negative for granulomas, cancers, hilar adenopathy, and organomegaly. Radiographs revealed extensive arthritis and periarticular erosions in bilateral hands and periarticular erosions on bilateral elbows (Image 2).

A bone marrow biopsy demonstrated normocellular marrow with trilineage hematopoiesis and was negative for Non-Hodgkin Lymphoma, plasma cell dyscrasia, acute leukemia, or high-grade myelodysplastic syndrome. Flow cytometry was also unremarkable.

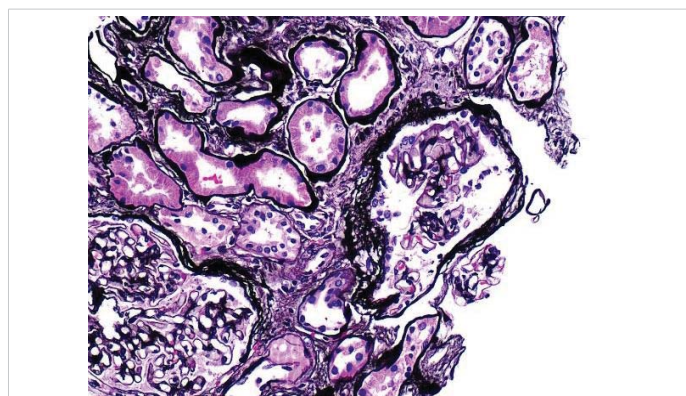
A renal biopsy was performed mainly to rule out limited renal sarcoid since there was no evidence of sarcoid disease anywhere. The patient had sterile pyuria and subnephrotic proteinuria. The biopsy showed severe arterionephrosclerosis, the cause of his CKD (Images 4-6). There was no evidence of granulomatous interstitial nephritis, the typical finding of sarcoid, and no microtophi. A repeat debulking of an elbow tophus showed extensive granulomas (Image 3).



**Image 2:** Bilateral Hand X-Rays. There is joint space narrowing with osseous cysts and extensive periarticular erosions. Carpal crowding with erosive changes within the ulnar styloid process. Moderate to severe circumferential soft tissue swelling and edema are suspected surrounding the hand and the wrist.

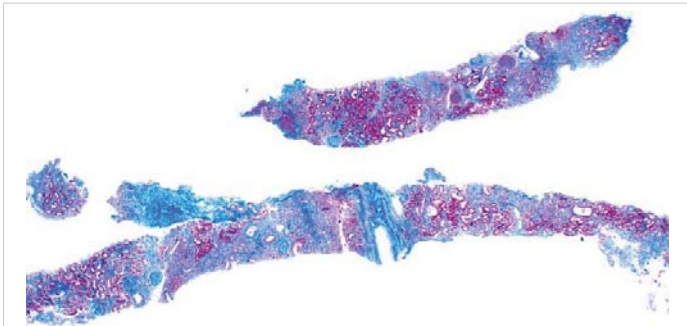


**Image 3:** Two magnifications of the elbow tophus showing extensive granulomas.

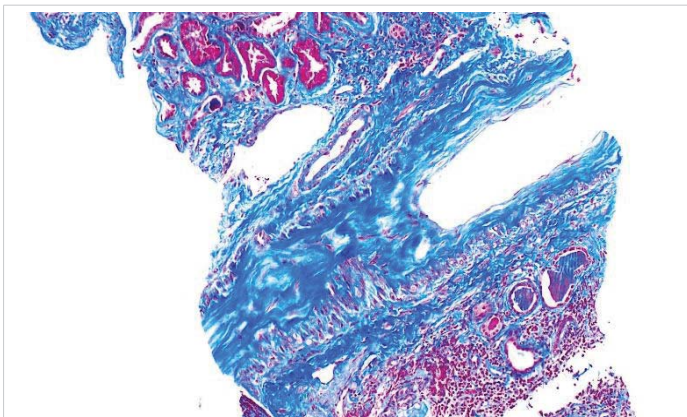


**Image 4:** Kidney biopsy. The most striking finding was severe arterial nephrosclerosis, the cause of his CKD, with moderate interstitial fibrosis and tubular atrophy. There was no evidence of granulomatous interstitial inflammation or gouty microtophi. Immunofluorescence and electron microscopy were negative.





**Image 5:** Kidney biopsy. The most striking finding was severe arterial nephrosclerosis, the cause of his CKD, with moderate interstitial fibrosis and tubular atrophy. There was no evidence of granulomatous interstitial inflammation or gouty microtophi. Immunofluorescence and electron microscopy were negative.



**Image 6:** Kidney biopsy. The most striking finding was severe arterial nephrosclerosis, the cause of his CKD, with moderate interstitial fibrosis and tubular atrophy. There was no evidence of granulomatous interstitial inflammation or gouty microtophi. Immunofluorescence and electron microscopy were negative.

The clinical impression was hypercalcemia due to excessive 1,25-dihydroxyvitamin D produced in the granulomas of the gouty tophi. Prednisone was started at 40 mg daily and then was gradually tapered to 10 mg daily. Febuxostat was added to control serum urate. Following 4 months of treatment, the patient felt more energetic, and lab parameters improved. Serum calcium and uric acid decreased to 9.4 mg/d and 6.2 mg/dl respectively, serum 1,25-dihydroxyvitamin D normalized to 42.1 pg/ml, and ACE improved to 98 units/l. Serum creatinine decreased to 2.1 mg/dl.

## Discussion

Our patient presented with relatively long-standing hypercalcemia with minor symptoms. This occurred in the setting of severe tophaceous gout and possibly seronegative rheumatoid arthritis. The elevated serum 1,25 dihydroxyvitamin D is hard evidence that the pathogenic cause of hypercalcemia was excessive unregulated 1,25 dihydroxyvitamin D.

In normal states, 25-hydroxyvitamin D is hydroxylated to the active 1,25 dihydroxyvitamin D in renal proximal tubular cells through the enzyme  $1\alpha$ -hydroxylase. In hypercalcemia,

this conversion is inhibited. Elevated 1,25-dihydroxyvitamin D in the setting of hypercalcemia, as seen in this patient, points to abnormal unregulated extrarenal conversion, typically found in granulomatous states and lymphomas. In these cases, macrophages within granulomas exhibit  $1\alpha$ -hydroxylase activity independent of normal hormonal or hypercalcemia controls.

Sarcoidosis, fungal infections, and tuberculosis are the most common granulomatous diseases associated with hypercalcemia and excessive 1,25-dihydroxyvitamin D. These, and lymphomas were ruled out through the clinical presentation and work-up, including negative imaging studies, negative tuberculin test, and negative bone and kidney biopsies. The serum angiotensin-converting enzyme levels were elevated; this is neither sensitive nor specific for sarcoidosis [4].

Other rare causes of hypercalcemia mediated by elevated 1,25 dihydroxy vitamin D were unlikely [3,5].

In our patient's case, the extensive volume of granulomatous tophi was the most likely source of the excessive 1,25 dihydroxyvitamin D. There is evidence that macrophages and multinucleated cells in the granulomas of tophaceous gout exhibit increased  $1\alpha$ -hydroxylase activity, as is found in granulomatous diseases. Gallegos-Bayas et al found intense  $1\alpha$ -hydroxylase activity in biopsies of gouty tophi from three patients. The cells were confirmed to be CD-68-positive macrophages [6].

Table 1 shows the review of the literature on hypercalcemia and tophaceous gout. This includes five case reports, and a recent abstract presented at the American Society of Nephrology [6-11]. All patients had extensive tophi, and in five of six cases, hypercalcemia was symptomatic. Monosodium urate crystals and granulomas were present in the tophi in the 3 cases with data. Three of the six cases had evidence pointing to elevated serum 1,25-dihydroxy vitamin D as the cause of hypercalcemia. The other 3 cases each had another cause: immobilization, transient unexplained increase in parathyroid hormone-related protein (PTH-RP), and 'hypercalcemia independent of PTH'.

The two major causes of hypercalcemia, primary hyperparathyroidism and cancer, were ruled out in our patients. Parathyroid hormone was suppressed appropriately in the setting of hypercalcemia. Cancer-related hypercalcemia was unlikely given the relatively long duration of hypercalcemia with only minor symptoms, negative imaging studies, and bone marrow biopsy, the lack of M spike on immunofixation, and negative PTH-RP. Our patient's clinical picture ruled out other causes of hypercalcemia, namely excessive vitamin D intake, milk-alkali syndrome, immobilization, thyrotoxicosis, and adrenal insufficiency. After his extensive work-up, there was no clinical or histologic evidence for the typical causes of granulomatous diseases

**Table 1:** Review of the 6 cases found in the literature of hypercalcemia associated with tophaceous gout.

References	Age (Years)	Serum Calcium/Uric Acid (mg/dL)	Extensive Tophi	Granulomas in Tophi	Serum 1,25-Vitamin D*	Serum ACE	ULT/steroids	Reported cause of hypercalcemia
Gallegos-Bayas, et al. [6]	75	14.0/10.4	Yes	Yes	NI	Yes	Yes/Yes	Increased 1,25-Vitamin D
Rodriguez, et al. [7]	42	14.5/14.0	Yes	Yes	NI	ND	Yes/Yes	Transient increase PTH-RP
Sachdeva, et al. [8]	41	13.5/ND	Yes	Yes	Elevated	ND	Yes/Yes	Increased 1,25-Vitamin D
Hasbani, et al. [9]	62	11.7/11.3	Yes	ND	ND	Yes	Yes/Yes	PTH independent
Lee, et al. [10]	49	15.3/11.7	Yes	ND	NI	Normal	Yes/No	Immobilization
Gudlawar S American Society of Nephrology [11]	40	13.4/11.0	Yes	ND	Elevated	ND	Yes/Yes	Increased 1,25-Vitamin D

ND: No Data; NI: Normal; ACE: Serum Angiotensin Converting Enzyme; ULT: Urate Lowering Therapy

\* When measured during hypercalcemia

associated with hypercalcemia, including sarcoidosis, fungal or tubercular infections, and other diseases.

The joint deformities and radiographic findings of an inflammatory arthropathy suggested a diagnosis of seronegative Rheumatoid Arthritis (RA), especially arthritis robustus, aside from his gout. Hypercalcemia is a rare complication of rheumatoid arthritis. Whether these rare cases of hypercalcemia are associated with high RA disease activity or not is uncertain [12]. Oelzner et al found that increased bone resorption in patients with RA and high disease activity could be the main cause of hypercalcemia. This would lead to suppression of PTH, inhibition of  $1\alpha$ -hydroxylase activity, and subsequent low 1,25-dihydroxyvitamin D - not what was seen in our case [12].

## Conclusion

In summary, we describe a well-documented case of hypercalcemia in severe tophaceous gout related to excessive 1,25 dihydroxyvitamin D produced in the tophi granulomas. A few other case reports - all with heavy tophi burdens - described similar findings. Severe tophaceous gout should be considered a rare cause of hypercalcemia.

## Ethical obligation

IRB approval was not required and consent was obtained from the patient for sharing both images and the case.

## References

- Walker MD, Shane E. Hypercalcemia: A review. *JAMA*. 2022;328(16):1624–1636. Available from: <https://doi.org/10.1001/jama.2022.18331>
- Goltzman D. Pathophysiology of hypercalcemia. *Endocrinol Metab Clin North Am*. 2021;50(4):591-607. Available from: <https://doi.org/10.1016/j.ecl.2021.07.008>
- Motlaghzadeh Y, Bilezikian JP, Sellmeyer DE. Rare causes of hypercalcemia: 2021 update. *J Clin Endocrinol Metab*. 2021;106(11):3113-3128. Available from: <https://doi.org/10.1210/clinem/dgab504>
- Ungprasert P, Carmona EM, Crowson CS, Matteson EL. Diagnostic utility of angiotensin-converting enzyme in sarcoidosis: A population-based study. *Lung*. 2016;194(1):91-5. Available from: <https://doi.org/10.1007/s00408-015-9826-3>
- Jacobs TB, Bilezikian JP. Rare causes of hypercalcemia. *J Clin Endocrinol Metab*. 2005;90:6316–6322. Available from: <https://doi.org/10.1210/jc.2005-0675>
- Gallegos-Bayas G, Pascual-Pareja JF, Sanchez-Niño MD, Manzarbeitia F, Ortiz A. Undetectable serum calcidiol: Not everything that glitters is gold. *Clin Kidney J*. 2012;5(1):37-40. Available from: <https://doi.org/10.1093/ndtplus/sfr121>
- Rodríguez-Gutiérrez R, Zapata-Rivera MA, Rodríguez-Velver KV, Lavalle-Gonzalez FJ, Gonzalez-Gonzalez JG, Villarreal-Perez JZ. Severe hypercalcemia - Chronic tophaceous gout as the responsible cause? *Eur Endocrinol*. 2015;11(2):102-104. Available from: <https://doi.org/10.17925/ee.2015.11.02.102>
- Sachdeva A, Goeckeritz BE, Oliver AM. Symptomatic hypercalcemia in a patient with chronic tophaceous gout: A case report. *Cases J*. 2008;1(1):72. Available from: <https://doi.org/10.1186/1757-1626-1-72>
- Hasbani GE, Megahed A, Cassetta M. When tophaceous gout involves multiple organs: Challenges and solutions. *Acta Endocrinol (Buchar)*. 2023;19(1):131-132. Available from: <https://doi.org/10.4183/aeb.2023.131>
- Lee KA, Yoo WH. Immobilization hypercalcemia-associated acute renal failure in a patient with chronic tophaceous gout. *Ren Fail*. 2009;31(9):855-7. Available from: <https://doi.org/10.3109/08860220903151393>
- Gudlawar S. Hypercalcemia associated with severe tophaceous gout. *Fluids, Electrolytes, and Acid-base Disorders: Clinical*. 2023 Nov 4. Pennsylvania. SA-PO965. Available from: [https://journals.lww.com/jasn/citation/2023/11001/hypercalcemia\\_associated\\_with\\_severe\\_tophaceous.3249.aspx](https://journals.lww.com/jasn/citation/2023/11001/hypercalcemia_associated_with_severe_tophaceous.3249.aspx)
- Oelzner P, Lehmann G, Eidner T, Franke S, Müller A, Wolf G, Hein G. Hypercalcemia in rheumatoid arthritis: Relationship with disease activity and bone metabolism. *Rheumatol Int*. 2006;26(10):908-15. Available from: <https://doi.org/10.1007/s00296-005-0095-y>